

SUCCESS CASE DETAILS

Patient Name: **Mr. Srinivasan, 45/Male, Coimbatore.**

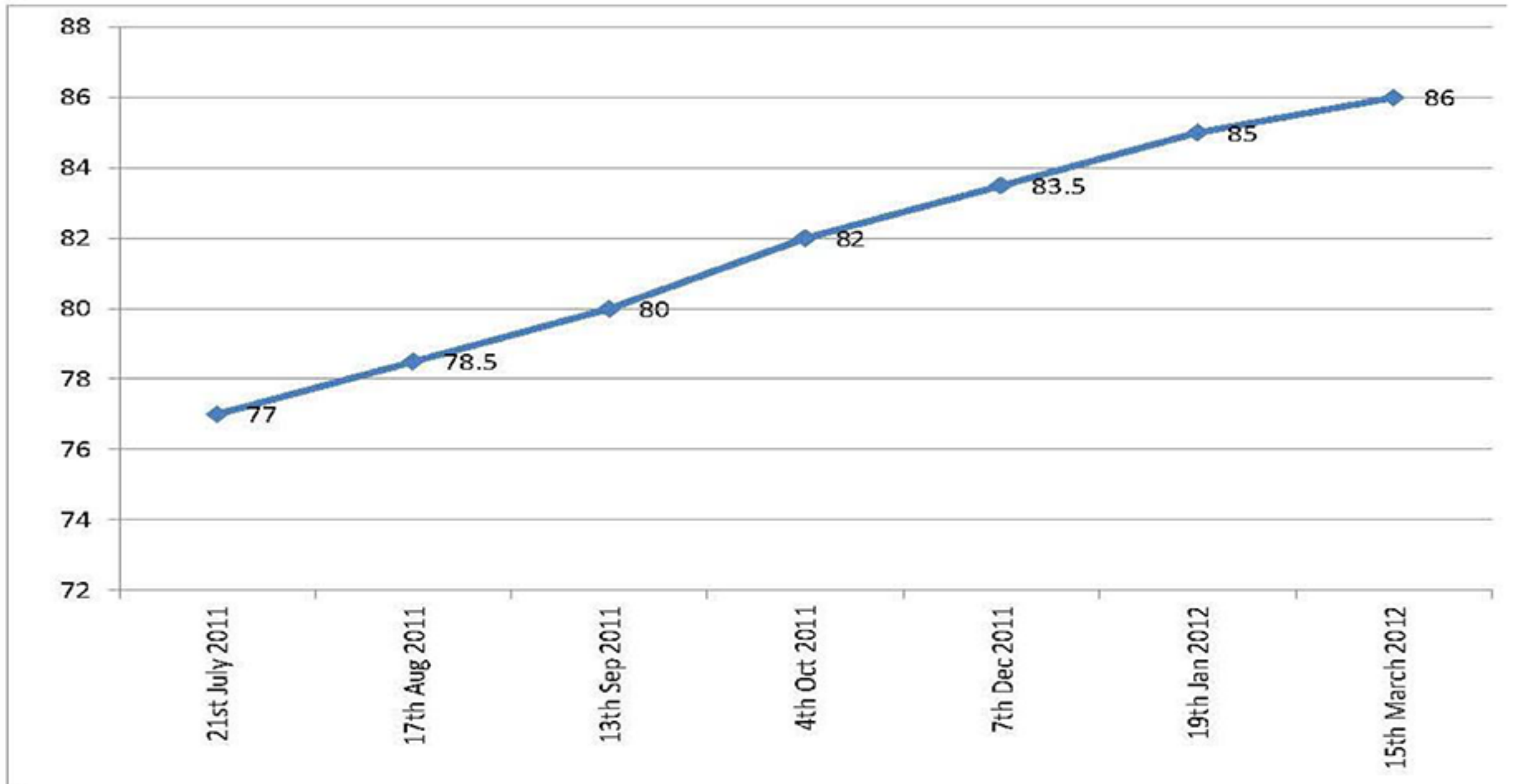
Diagnosis: Type II Diabetes. Since from 21-07-2011

Blood test	Normal values							
HbA1c	6-7 Good control	15.3	13.8	11.7	10.7	7.9	6.7	6.8
Sugar (F)	<110	380.6	296.3	218.5	167.4	99.1	125.6	128.3
Sugar (PP)	<160	467.38	413.98	339.22	303.62	203.94	161.22	164.78

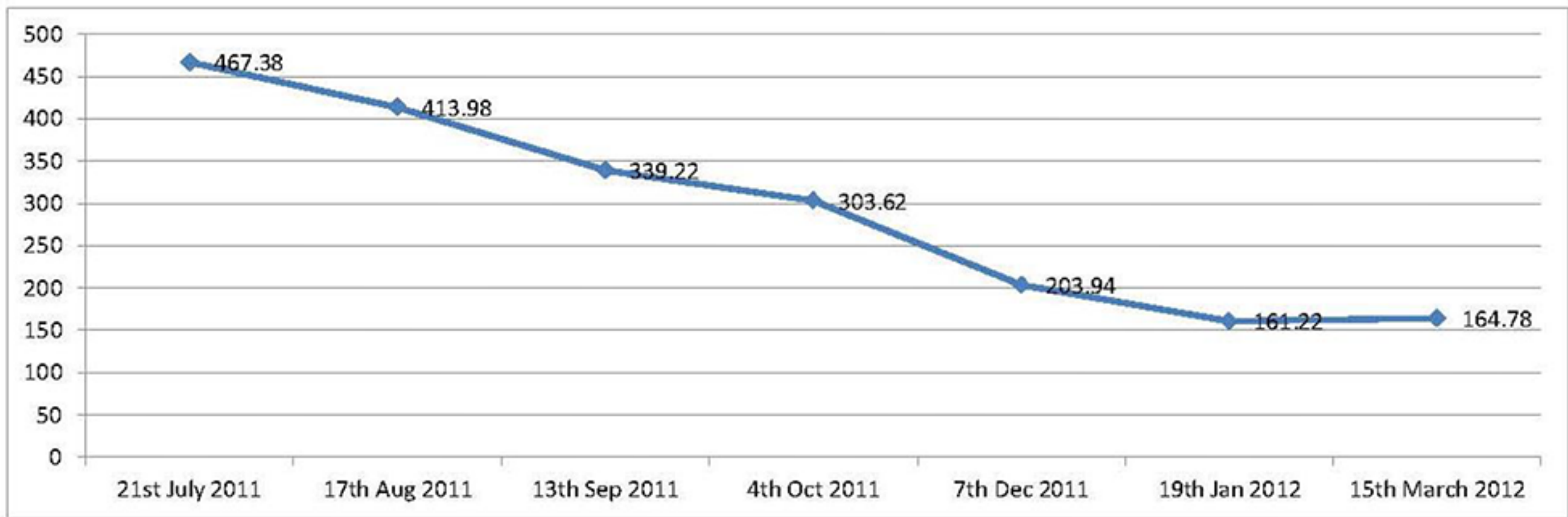
Medicines:

1. நிலவேம்பு குடிநீர், 2. ஆவாரை குடிநீர், 3. மதுமேக குடிநீர், 4. சீந்தில் மாத்திரை,
5. வில்வம் மாத்திரை. 6. மேகானில் மாத்திரை.

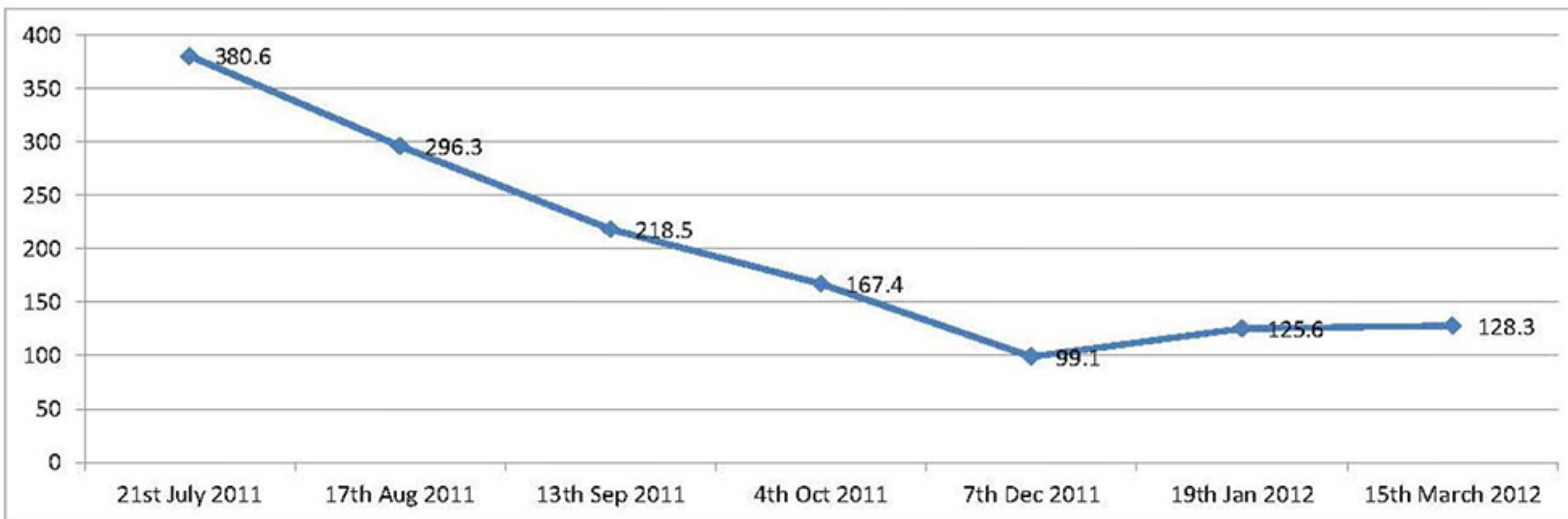Weight in Kg



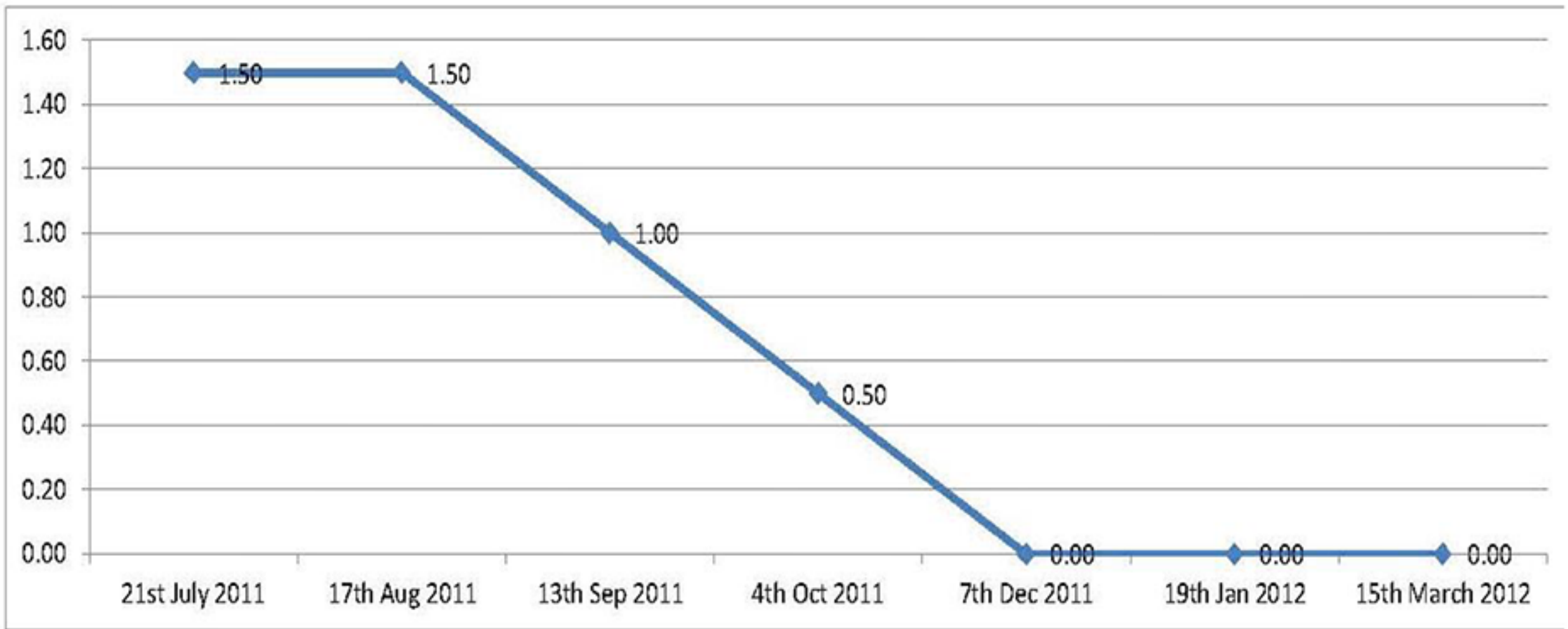
Mean Glucose level



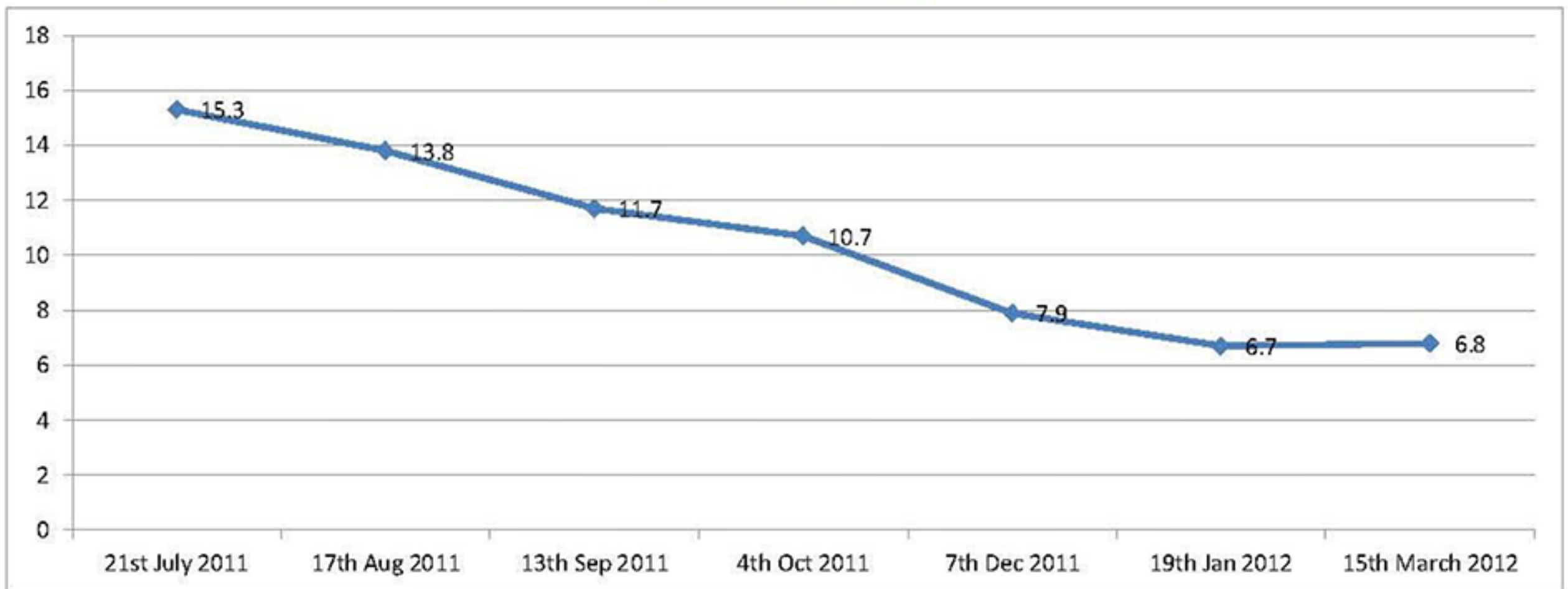
Glucose (Fasting)



Sugar in Urine



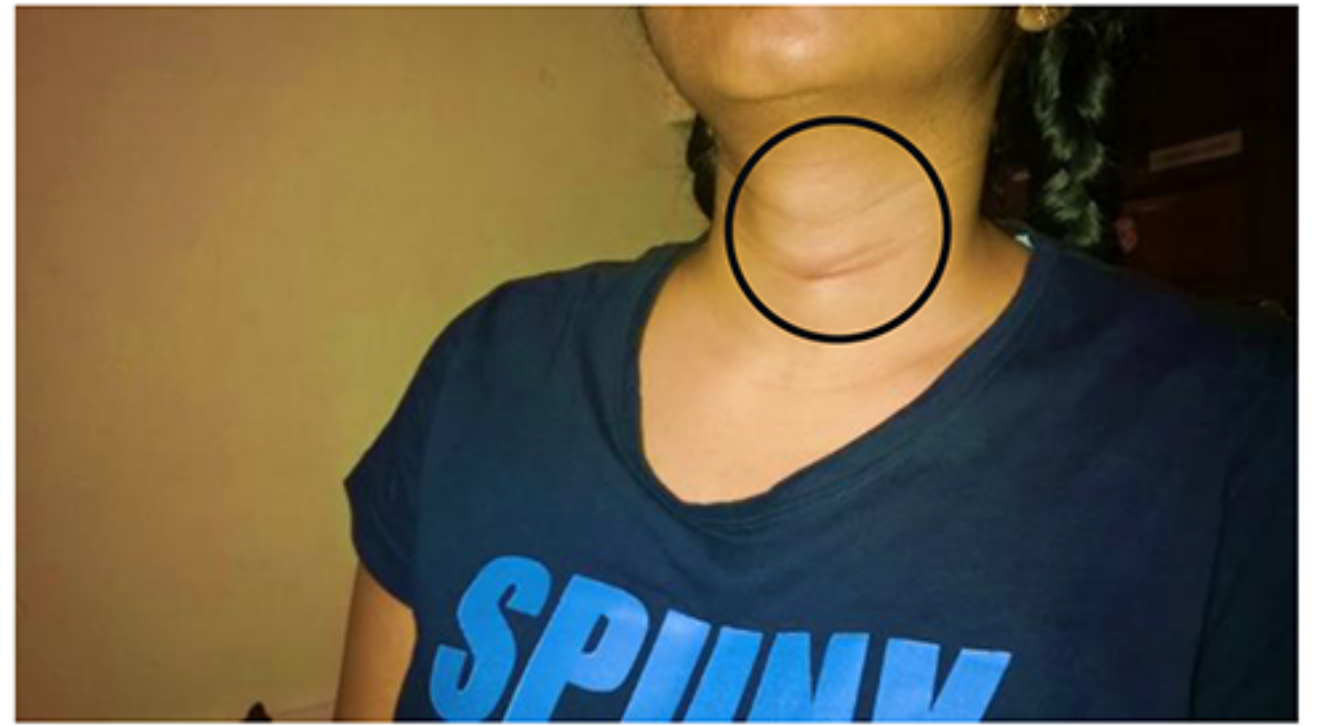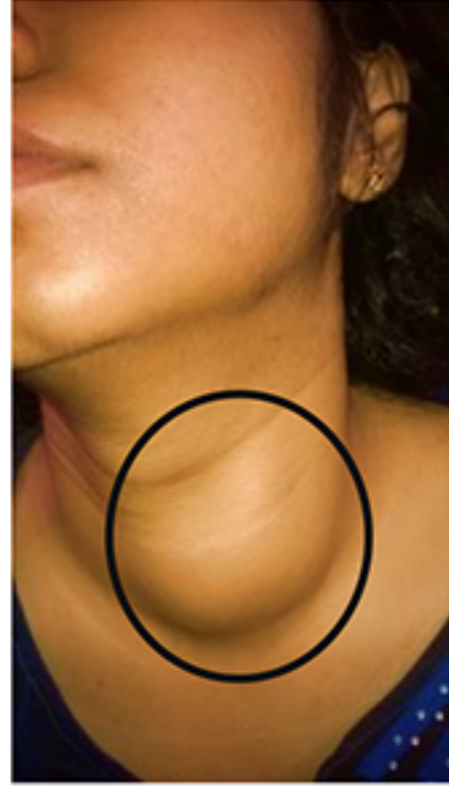
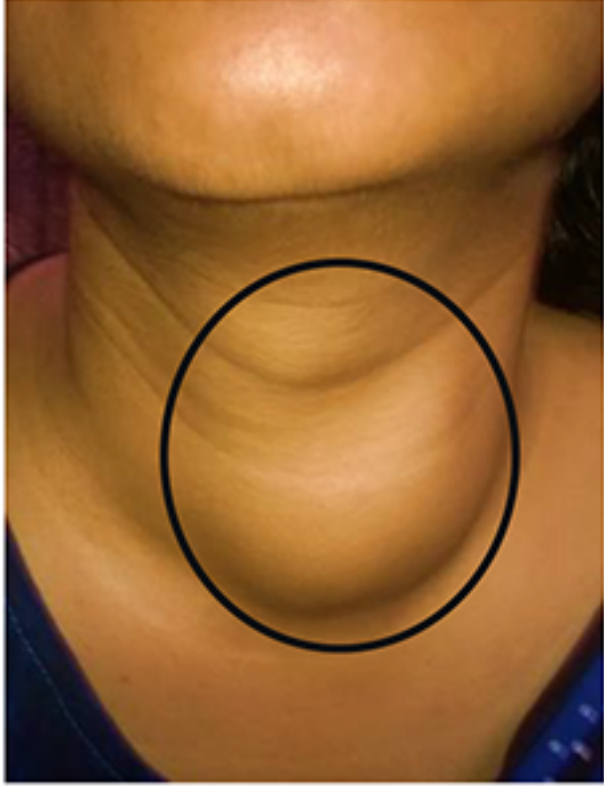HbA1C



SUCCESS CASE DETAILS...

Patient Name: **Abinethri, 25/F, Mumbai**

Diagnosis: The Focal collection / lymphnodal mass anteroinferior to left hemithyroid with hypodense lesion in liver and spleen, multiple nodule seen in paratracheal region.

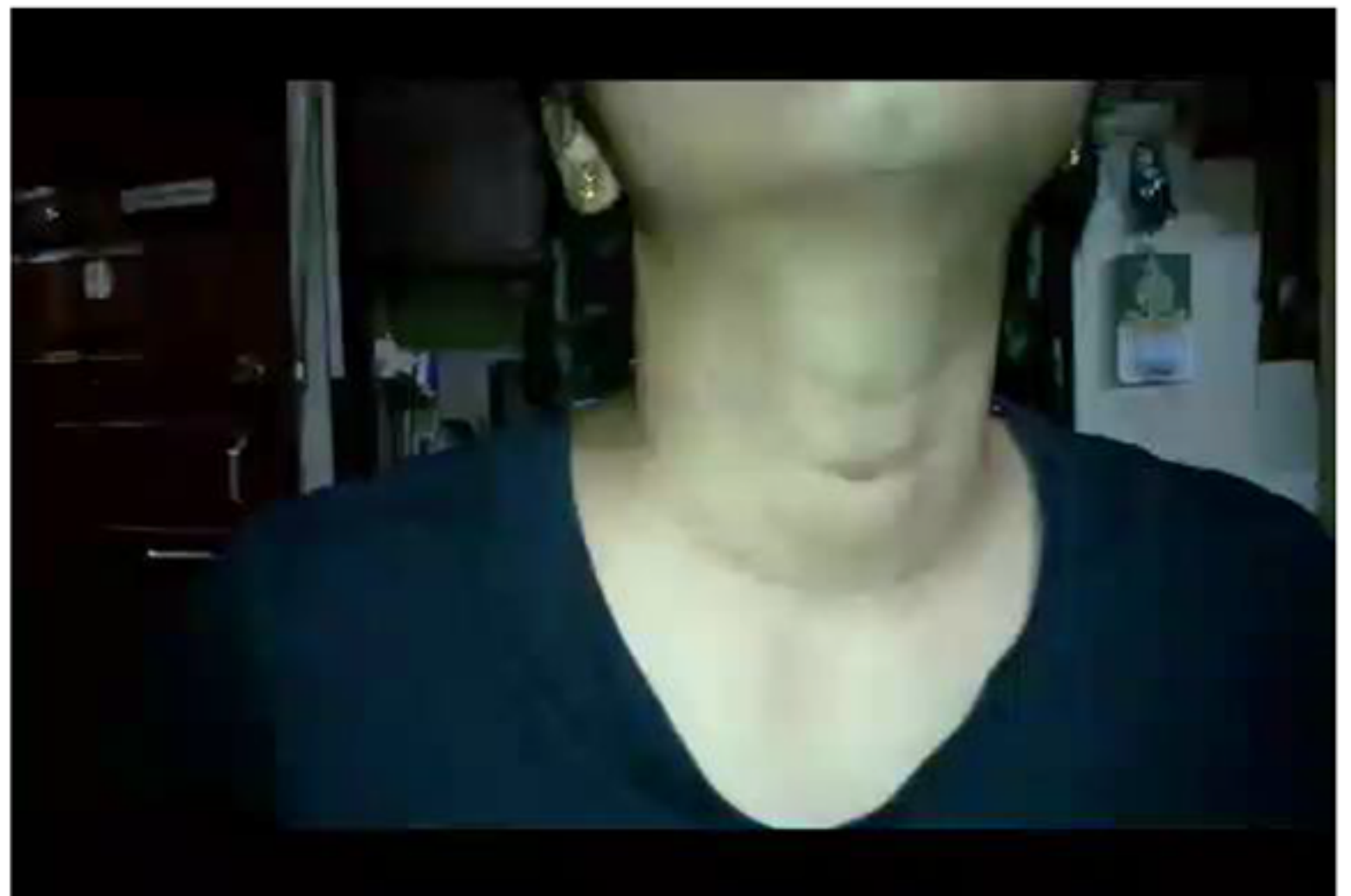


Since: 2.5 Years

Treatment period: 18-05-2013 to 25-11-2015

Medicines:

1. Kanchanara guggulu.tab,
2. Varanathi kasayam,
3. Aarumuga chenthuram,
4. Annapavala chenthuram,
5. Thiripalachuranam,
6. Seenthil kasayam,
7. Septilin tablet,
8. Sp megarayana chenthuram



SUCCESS CASE DETAILS...

Patient Name: **M.Rajamani 48/M, Kumaralingam, Udumalaipet.**

Diagnosis: Jaundice, Acute renal failure.

Medicines: சிறுபிளை + நீர்முள்ளி குடிநீர், நண்டுக்கல் பற்பம், புணர்நவா மண்டுரம், கரிசாலை கற்பம், கீழாநெல்லி கற்கம், வெடியுப்பு சுண்ணம், படிகார பற்பம், வெங்கார பற்பம், பிருகத்யாதி குடிநீர்

Blood test	04-07-2016	16-07-2016
Total Bilirubin	5.1mg/dl	1mg/dl
Direct Bilirubin	2.6mg/dl	0.4mg/dl
In direct Bilirubin	2.5mg/dl	0.6mg/dl
Creatinine	3.4mg	0.9mg/dl

SUCCESS CASE DETAILS...

Patient Name: **Mr. Rathinam 36/M, Komaralingam post, Udumalaipet.**

Diagnosis: Jaundice, Liver enlargement

Present Symptoms: weight loss, yellowish discoloration in eye and total body., yellow colored urine, Abdominal pain, loss of appetite, minimal ascites.

Medicines:

1. மண்டுராதி குடிநீர்,
2. நண்டுக்கல் பற்பம்,
3. புணர்நவா மண்டுரம்,
4. கரிசாலை கற்பம்,
5. கீழாநெல்லி கற்கம்,
6. வெடியுப்பு சுண்ணம்,
7. Liv52.syrup,
8. நாயுருவி குடிநீர்

Blood Test	Before treatment 24-06-2015	After treatment 04-10-2015
Total bilirubin	31mg/dl	1.2
Direct bilirubin	13mg/dl	0.9
Indirect bilirubin	11.2mg/dl	0.5
SGOT	224	19
SGPT	126	24
ALP	296	134

Duration: 100 Days

SUCCESS CASE DETAILS...

Name: Dinesh, 7Y / Male

Nemmara, Kerala

Since: 2 Years

Diagnosis: Rectal prolapse

Sym: No Pain, No bleeding,

No burning sensation, Mild Constipation

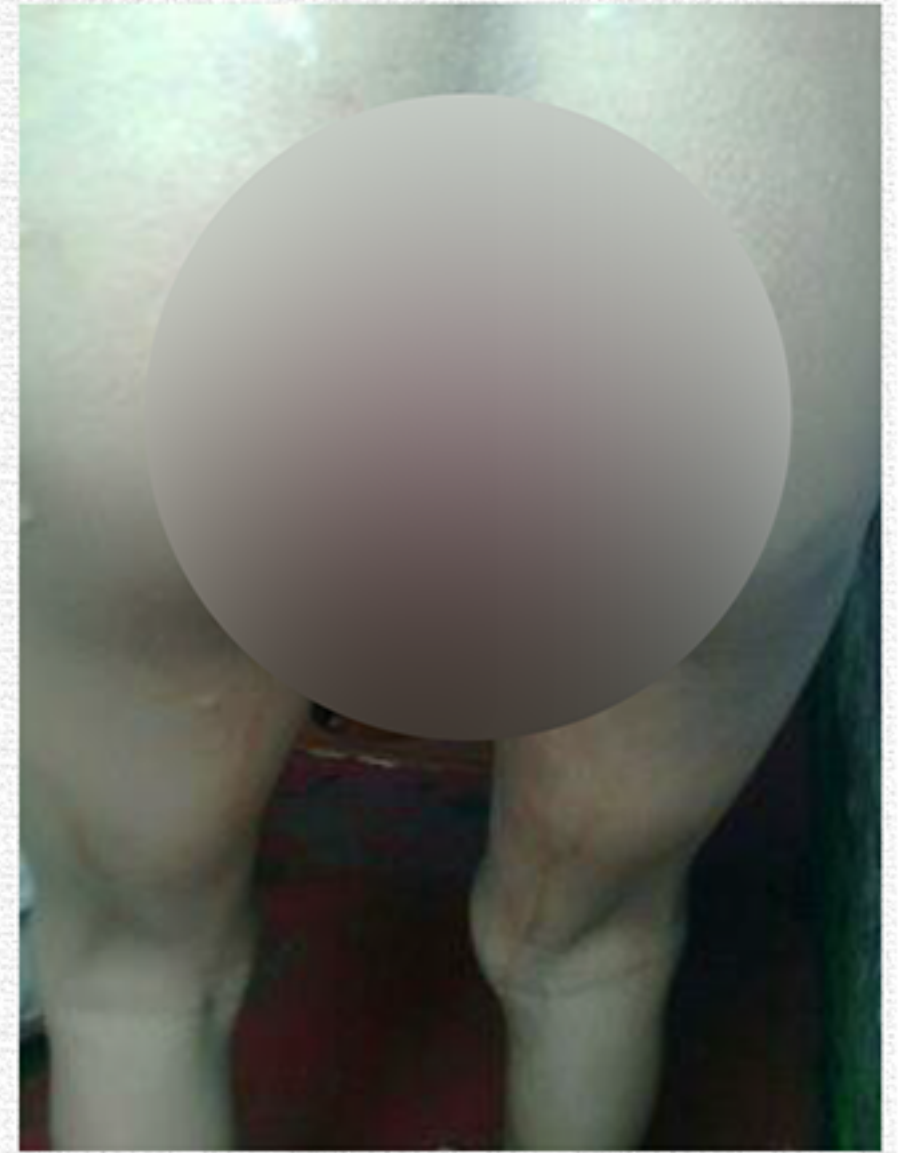Nadi: Pitham

Duration of treatment: 21-01-2017 to 02-03-2017

Medicines: Adathodai Ennai

Dosage: Morning / Night 1Tsp (before food)

Result: Patient get completely recovered.



SUCCESS CASE DETAILS...

Name: Saraswathi, 44Y/Female

Trichy

Since: 6 Years

Diagnosis: Lymph node enlargement in neck region-?Thyroid nodule
?Lymphoidal mass.

O/E: Soft and enlargement of the nodule

Sym: No pain, Weight reduced,

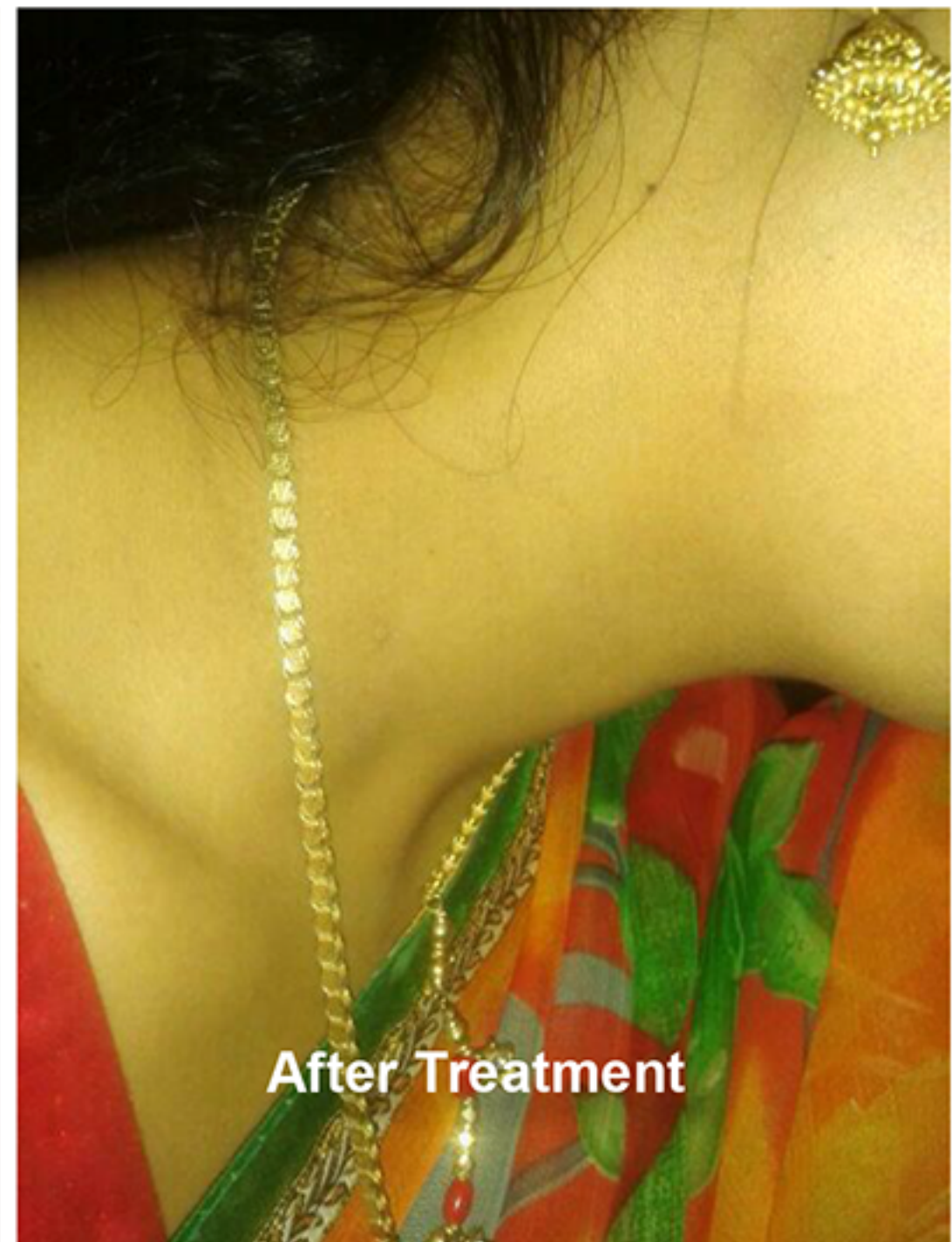
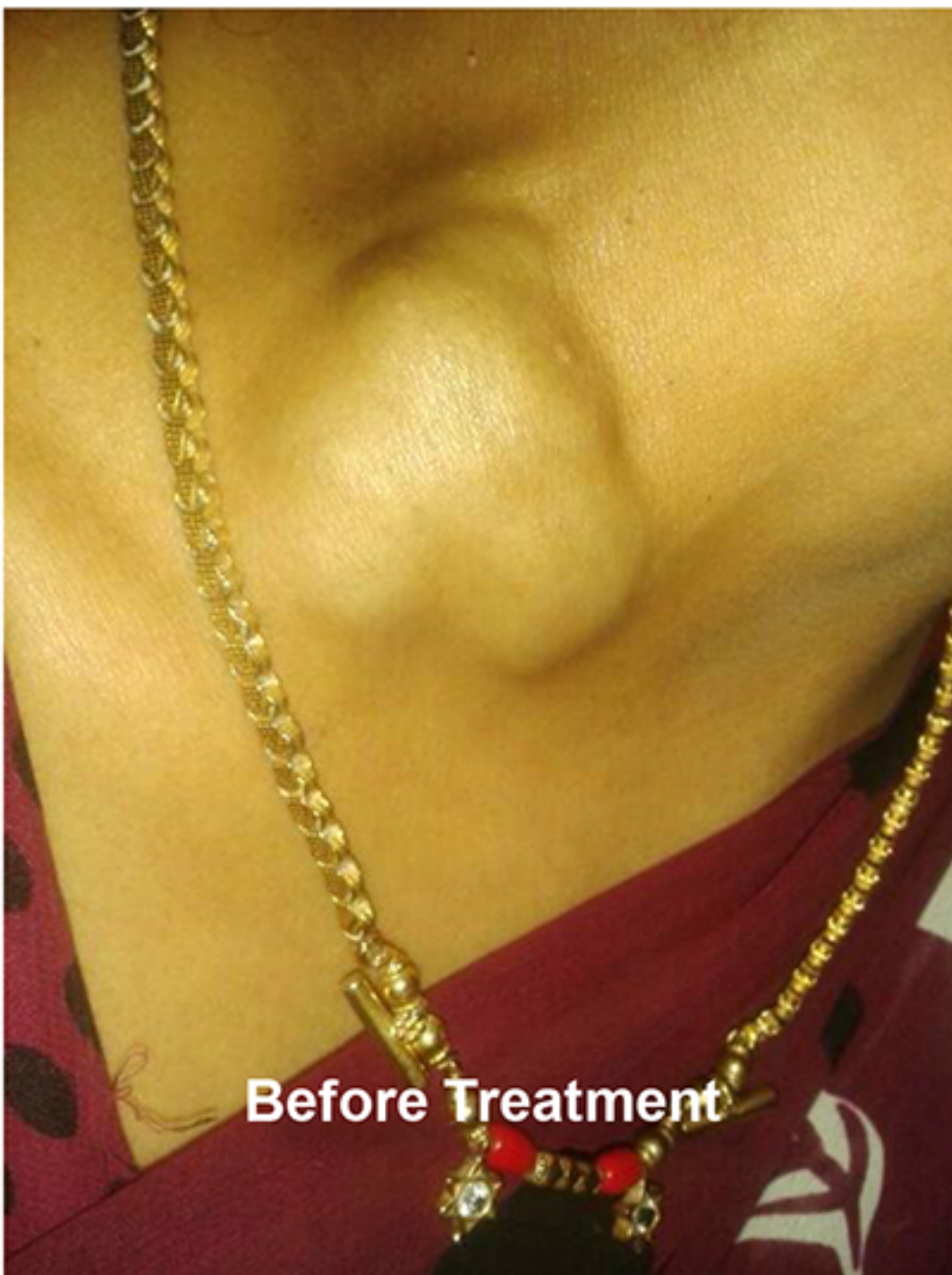
T3, T4, TSH-Level are Normal, Other parameters are Normal

Duration of treatment: 22-07-2017 to 08-02-2018

Medicines:

1. Thripala.Tab – 2 tablets morning and night after food
2. Kanchanara gugulu.Tab - 2 tablets morning and night after food
3. Varanathi kasayam – 15ml morning and night before food with hot water
4. Neeradimuthu vallathy.Capsule – 1 cap morning and night after food
5. Karisalai karpam tablet – 2 tablets morning and night after food
6. Kalarchi chooranam – 1gm morning and night after food with milk
7. Thamirakattu chenthuram with Karisalai chooranam

Result: Enlargement was reduced



SUCCESS CASE DETAILS...

Name: Kathirvel, 54Y / Male

Coimbatore

Since: 4.5 Years

Diagnosis: Varicose ulcer in lower leg

O/E: Wound in lower leg, varicose veins

H/O: No DM, HT

Sym: Mild Pain, Mild burning sensation, Mild itching

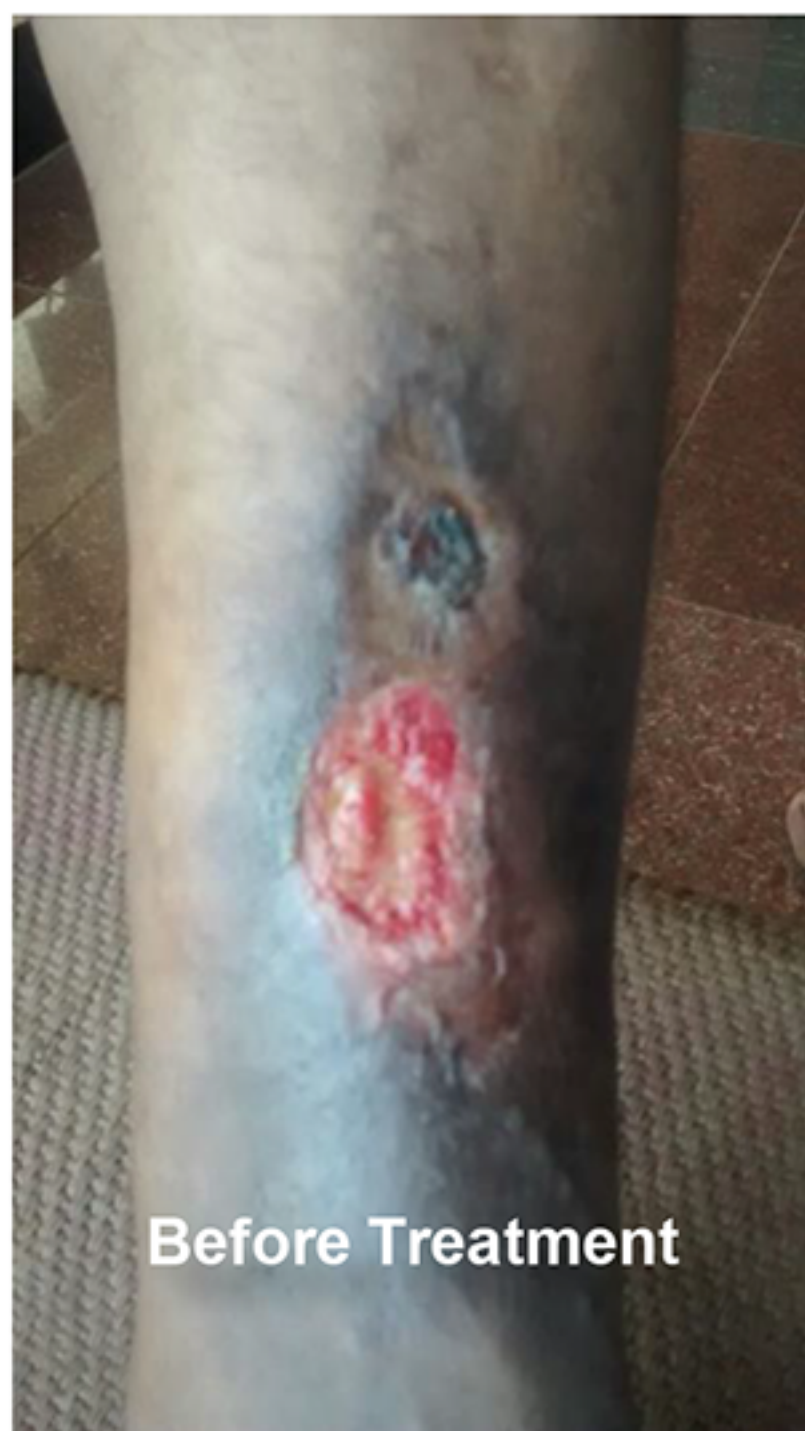Nadi: Pithavatham

Duration of treatment: 03-07-2016 to 24-08-2016

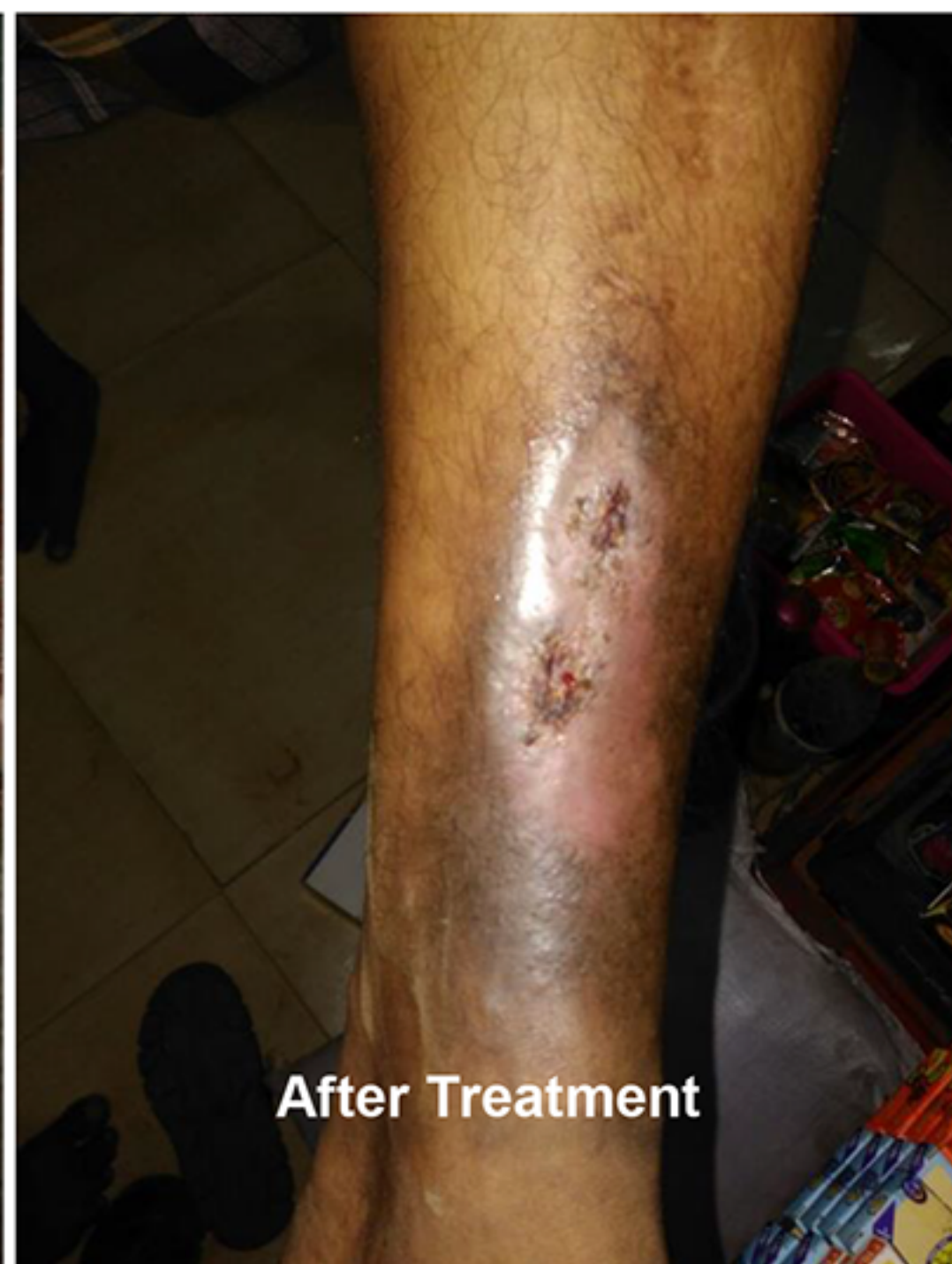Medicines:

1. Agasthiar kulambu purgation
2. Kaisora gugulu.Tab – 2 tab morning and night after food
3. Nilavembu + Neermulli kudineer – 60ml - morning and night before food
4. Tablet.septilin - 2 tab morning and night after food
5. Centis.Tab - 2 tab morning and night after food
6. Capsule.RGM – 1 cap. morning and night after food
7. Viranasanjeevi thylam(spl) – External application

Result: Reduced wound



Before Treatment



After Treatment

SUCCESS CASE DETAILS...

- Patient name: Mrs.R.Padmapriya / 25-F
- Diagnosis: Bilateral Polycystic ovarian syndrome and primary infertility
- Present History: married after 3 years no issues – PCOS for the past 3 years
- Present Symptoms: Irregular menstrual cycle, stomach pain during menstruation, general weakness, and pimples in face, white discharge, and tiredness and painful ovulation.
- Medical History: Allopathy treatment taken for this in the past history .no result.

Treatment:

1. Siddha treatment 2. Vethathiri maharishi`s Kayakalpa yoga practices.

Siddha medicines:

- 1. Agathiyar kulambu 2. Malaivembaathi thylam 3. Pooranachandrodhaya tablet
- 4. Thirikadugu chooranam 5. Arumugachendooram, 6. Kalarchi chooranam, 7. Kanchanara gugulu, 8. Sathavari legiyam
- Duration of the treatment: From 28-02-2013 to 16-07-2013
- Result: PCOS get cured.....Patient gets conceived Twin baby`s was born.

Name : Mrs. PADMAPRIYA.R Age : 25 Yr. Sex : F
Ref. By : Dr. SHANTHILS BSMS Date : 28/02/13
Thanking you for referring

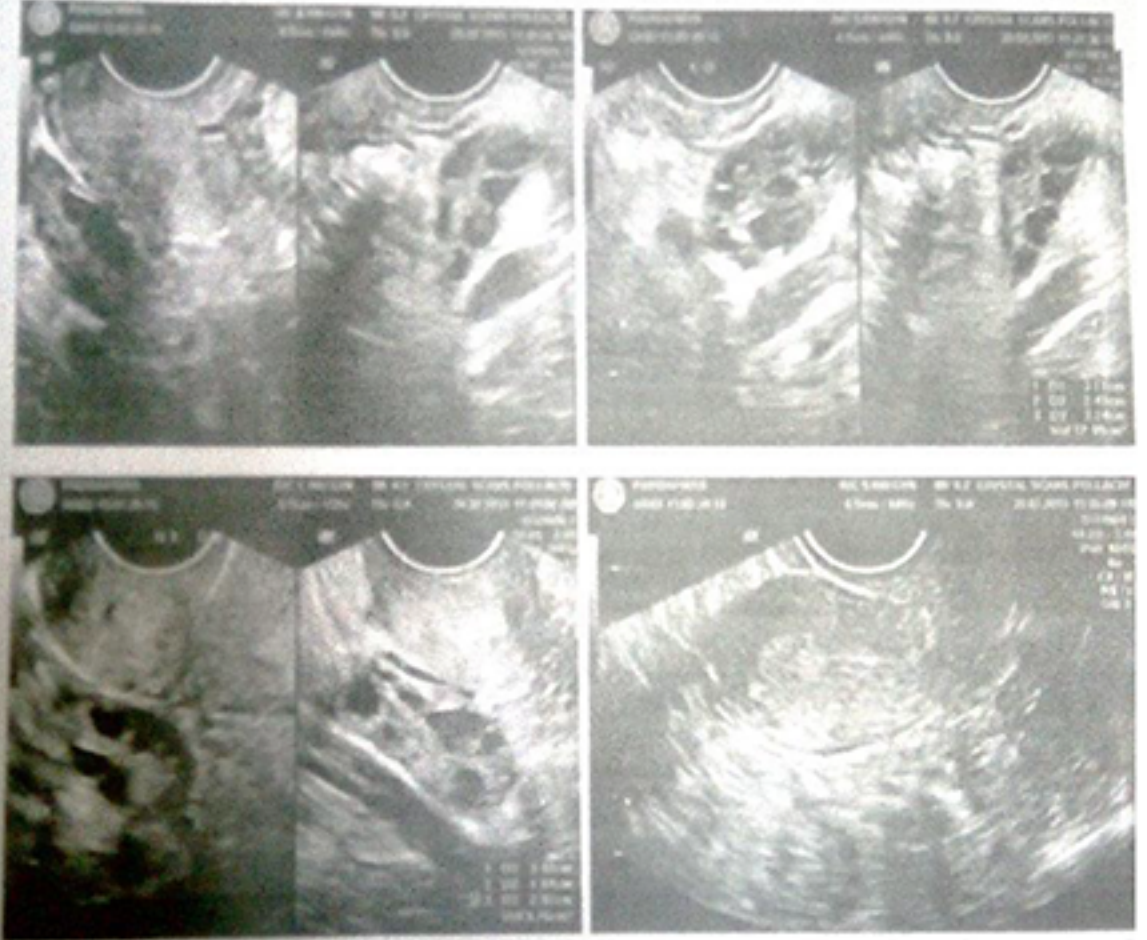
**TRANSVAGINAL ULTRASOUND
PELVIS**

Transvaginal ultrasound done with 5 - 9 MHz probe reveals :

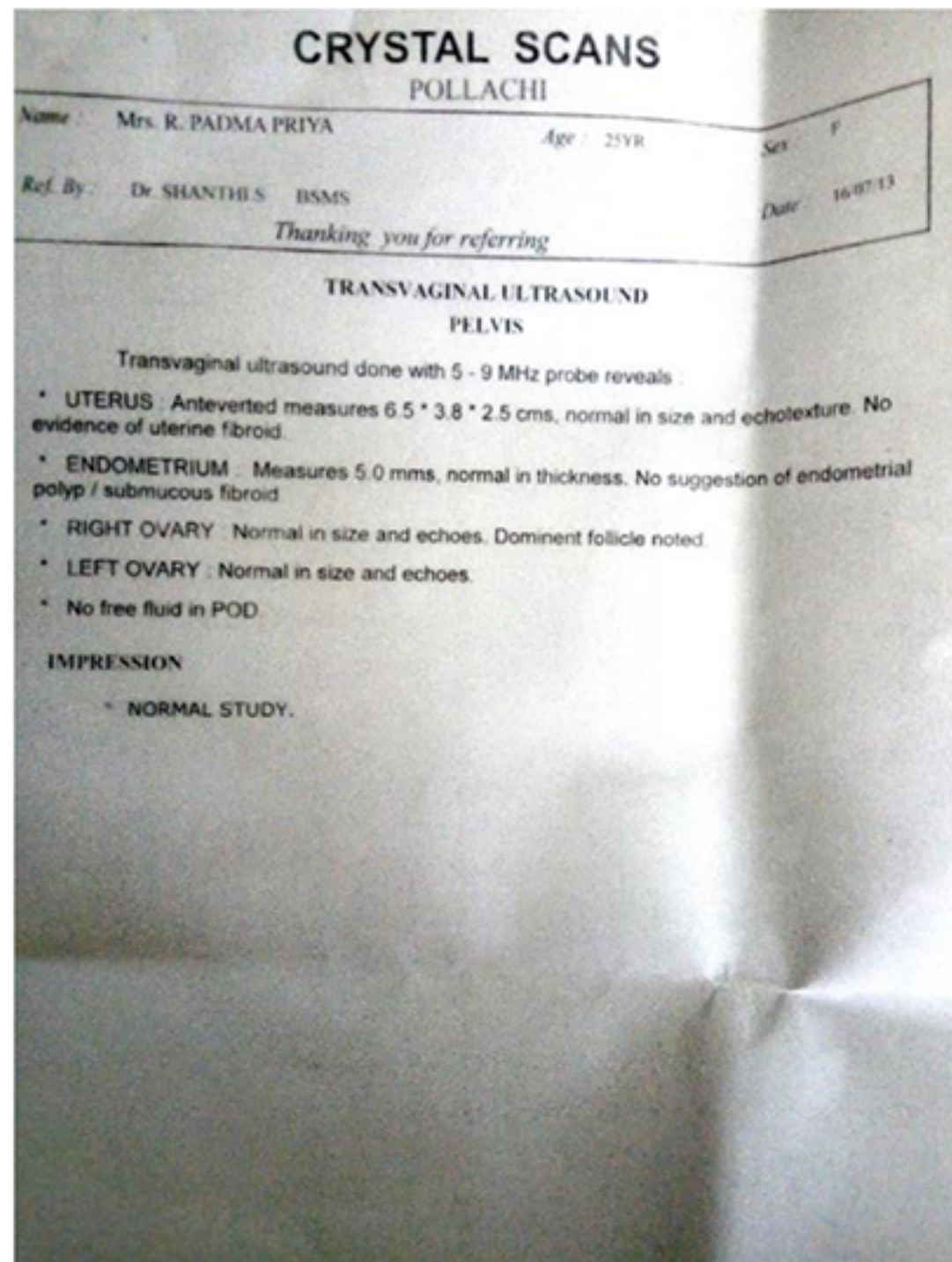
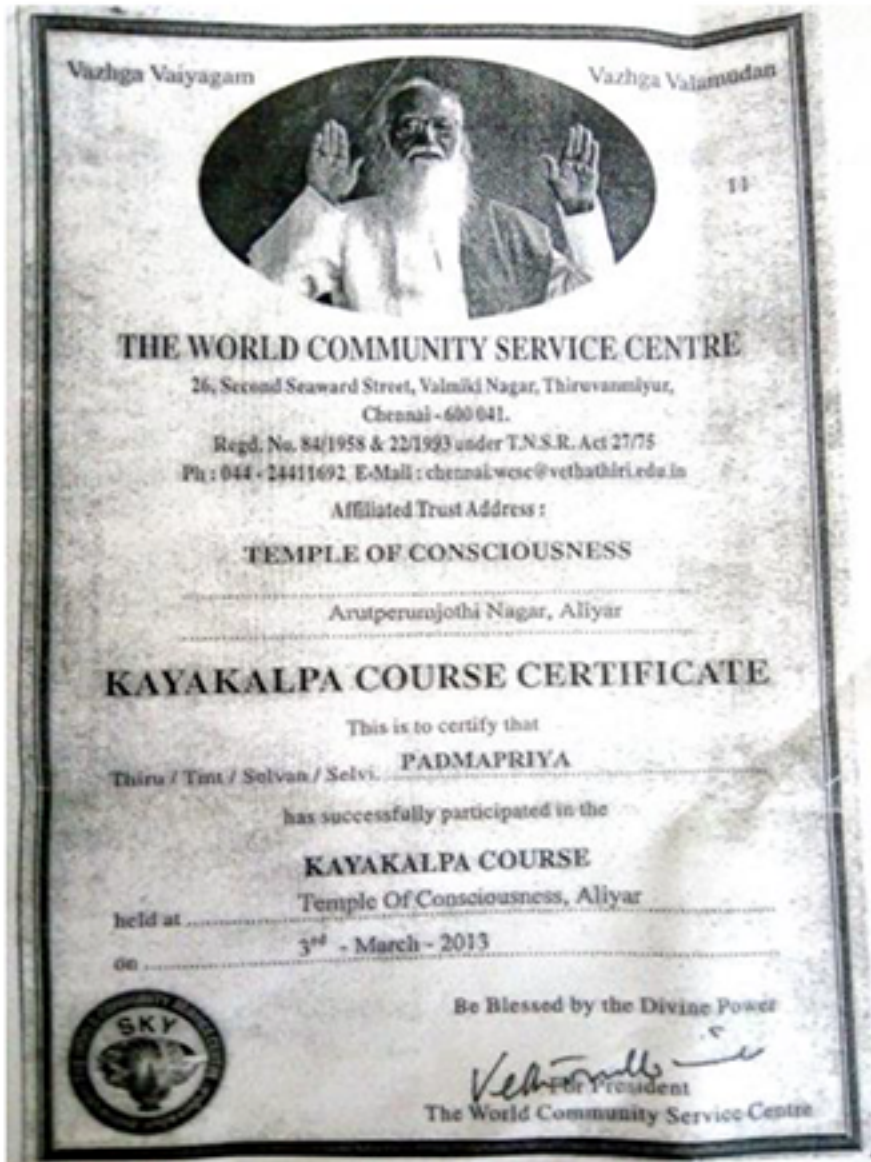
- UTERUS : Anteverted, normal in size and echotexture. No evidence of uterine fibroid.
- ENDOMETRIUM : Measures 9.0 mms, normal in thickness. No suggestion of endometrial polyp / submucous fibroid.
- RIGHT OVARY : Measures 3.4 * 2.9 * 1.8 cms, enlarged in size (volume 10 cc) with increased stromal echoes. Multiple small peripheral follicles noted. No dominant follicle.
- LEFT OVARY : Measures 3.2 * 3.1 * 2.4 cms, enlarged in size (volume 13 cc) with increased stromal echoes. Multiple small peripheral follicles noted. No dominant follicle.
- No free fluid in POD.

IMPRESSION

- * BILATERAL POLYCYSTIC OVARIES.



REPORTS



SUCCESS CASE DETAILS

Patient Name: **Mr. Srinivasan, 45/Male, Coimbatore.**

Diagnosis: Type II Diabetes

Blood test	Normal values							
HbA1c	6-7 Good control	15.3	13.8	11.7	10.7	7.9	6.7	6.8
Sugar (F)	<110	380.6	296.3	218.5	167.4	99.1	125.6	128.3
Sugar (PP)	<160	467.38	413.98	339.22	303.62	203.94	161.22	164.78

Medicines:

1. நிலவேம்பு குடிநீர், 2. ஆவாரை குடிநீர், 3. மதுமேக குடிநீர், 4. சீந்தில் மாத்திரை,
5. வில்வம் மாத்திரை.

SUCCESS CASE DETAILS...

- ❖ Patient Name: **P.Alagesan , Trichy- 3.** Cell: 9047696707.
- ❖ Diagnosis: Polycystic ovarian syndrome and primary infertility.
- ❖ Present History: married after 3 years no issues – Pcos for the past 3 years
- ❖ Present Symptoms: Irregular menstrual cycle, stomach pain during menstruation, general weakness, and pimples in face, white discharge, and tiredness and irregular menstruation.
- ❖ Medicines: 1. Agathiyar kulambu 2. Malaivembaathi thylam 3. Pooranachandrodhaya tablet 4. Thirikadugu chooranam 5. Arumugachendooram.

SUCCESS CASE DETAILS...

Patient Name: **Mr. Mohanraj, 33/M, Uthukuli, Pollachi.**

Diagnosis: Jaundice, Hepatitis B virus

Present Symptoms: weight loss, yellowish discoloration in eye, yellow colored urine, Abdominal pain, loss of appetite.

Medicines: மண்டுராதி குடிநீர்,
நண்டுக்கல் பற்பம்,
புணர்நவா மண்டுரம்,
கரிசாலை கற்பம்,
கீழாநெல்லி கற்கம்,
வெடியுப்பு சுண்ணம்,
படிகார பற்பம்.

Test	Before treatment 22-02-2016	After treatment 17-05-2016
Total bilirubin	7.6mg/dl	0.9
Direct bilirubin	1.6mg/dl	0.2
Indirect bilirubin	6.0mg/dl	0.7
SGOT	171	21
SGPT	74	36
ALP	216	122
HBSAG	Positive	Negative



SUCCESS CASE DETAILS...

Patient Name: **Mr. Rathinam 36/M, Komaralingam post, Udumalaipet.**

Diagnosis: Jaundice, Liver enlargement

Present Symptoms: weight loss, yellowish discoloration in eye and total body., yellow colored urine, Abdominal pain, loss of appetite, minimal ascites.

Medicines: மண்டுராதி குடிநீர்,
நண்டுக்கல் பற்பம்,
புணர்நவா மண்டுரம்,
கரிசாலை கற்பம்,
கீழாநெல்லி கற்கம்,
வெடியுப்பு சுண்ணம்,
Liv52.syrup, நாயுருவி குடிநீர்
Duration: **90 Days**

Blood Test	Before treatment	After treatment
Total bilirubin	31mg/dl	1.2
Direct bilirubin	13mg/dl	0.9
Indirect bilirubin	11.2mg/dl	0.5
SGOT	224	19
SGPT	126	24
ALP	296	134

SUCCESS CASE DETAILS...

Patient Name: **Mrs. Yasmin Mohammed 39/F, Anaimalai**

Diagnosis: Bulky Uterus with Endometrial thickening.

Medicines: 1. Agathiyar kulambu 2. Malaivembaathi thylam 3. Varanathi kashayam.
4. Thirikadugu chooranam 5. Arumugachendooram 6. Aloes compound tab.
7. Kanchanara guggulu.tab

Duration of the treatment: 26-9-15 to 29-3-16.

Scan result: No significant abnormality detected.



SUCCESS CASE DETAILS...

Patient Name: **Mrs. Suganya, 25/F, Kottur**

Diagnosis: Polycystic ovarian syndrome and Secondary infertility.

Medicines: 1. Agathiyar kulambu 2. Malaivembaathi thylam 3. Pooranachandrodhaya
tablet 4. Thirikadugu chooranam 5. Arumugachendooram 6. Sathaveri lehiyam
7. Aswagandha thylam

Duration of the treatment: 8-7-15 to 14-11-15

Result: Patient get conceived. Male baby was born.



SUCCESS CASE DETAILS...

Bioline Laboratory

SID No : 017120 Patient ID : P000906

Collected Date : 30/10/2012 18:12
Received Date : 30/10/2012 18:12
Reported Date : 01/11/2012 10:40
Page 1/1

Specimen Test Name Result Units Reference Range/Method

IMMUNOLOGY	FSH	5.08	IU/L	MALE : 0.95 - 11.95 FEMALE: Follicular Phase : 3.03 - 8.08 Mid-Cycle Peak : 2.35 - 16.69 Luteal Phase : 1.28 - 5.24 Post Menopausal : 26.72 - 133.41 (CMA)
SERUM	LH	22.40	IU/L	MALE : 1.24 - 8.75 FEMALE: Follicular Phase : 2.39 - 6.60 Mid-Cycle Peak : 9.36 - 74.24 Luteal Phase : 0.90 - 9.33 Post Menopausal : 15.49 - 64.57 (CMA)

End of the Report

Bioline Laboratory

SID No : 017140 Patient ID : P000912

Collected Date : 10/05/2013 18:11
Received Date : 10/05/2013 18:11
Reported Date : 10/05/2013 10:11
Page 1/1

Specimen Test Name Result Units Reference Range/Method

IMMUNOLOGY	FSH	5.08	IU/L	MALE : 0.95 - 11.95 FEMALE: Follicular Phase : 3.03 - 8.08 Mid-Cycle Peak : 2.35 - 16.69 Luteal Phase : 1.28 - 5.24 Post Menopausal : 26.72 - 133.41 (CMA)
SERUM	LH	3.90	IU/L	MALE : 1.24 - 8.75 FEMALE: Follicular Phase : 2.39 - 6.60 Mid-Cycle Peak : 9.36 - 74.24 Luteal Phase : 0.90 - 9.33 Post Menopausal : 15.49 - 64.57 (CMA)

End of the Report



Name: A. Hazeena 20/F, Anaimalai
Diagnosis: PCOS

LH level: 22.40 (before treatment)

LH level: 3.90 (after treatment)

Normal value: 2.39 to 6.6 in
follicular phase.

SUCCESS CASE DETAILS...

Patient Name: **Mrs.Rajalakshmi 33/F, Mumbai.**

Diagnosis: Polycystic ovarian syndrome and primary infertility.

Present Symptoms: Irregular menstrual cycle, stomach pain during menstruation, general weakness, pimples in face, white discharge, tiredness, painful ovulation, obesity.

Medicines: 1. Agathiyar kulambu 2. Malaivembaathi thylam
3. Pooranachandrodhaya tablet 4. Thirikadugu chooranam
5. Arumugachendooram 6. Sathaveri lehiyam 7. Aswagandha thylam.

Duration of the treatment: 2 months From 9.5.15 To 24.8.15

Result: Pcos get cured.



SUCCESS CASE DETAILS...

Patient Name: **Sasikala 27/F, Pollachi**

Diagnosis: Polycystic ovarian syndrome and Fibroid uterus.

Present Symptoms: Irregular menstrual cycle, stomach pain during menstruation, general weakness, white discharge, and tiredness and painful ovulation, obesity.

Medicines: 1. Agathiyar kulambu 2. Malaivembaathi thylam
3. Pooranachandrodhaya tablet 4. Thirikadugu chooranam
5. Arumugachendooram 6. Sathaveri lehiyam 7. Aswagandha thylam
8. Neeradimuthu vallathi cap.

Duration of the treatment: 7.10.15 to 18.3.16 (5 ½ months)

Result: Pcos get cured. Uterus fibroid get cured.

Patient taking siddha medicines for infertility treatment.

